

See discussions, stats, and author profiles for this publication at: <https://www.researchgate.net/publication/283271802>

Strangulated hernia with bowel perforation through a defect of the broad ligament Case Report

Article · August 2015

DOI: 10.4103/2278-9596.167522

CITATIONS

0

READS

38

5 authors, including:



Mohammad Aladaileh

University of Jordan

8 PUBLICATIONS 0 CITATIONS

[SEE PROFILE](#)



Mohammad Rashdan

University of Jordan

3 PUBLICATIONS 0 CITATIONS

[SEE PROFILE](#)



Awni Shahait

Wayne State University

12 PUBLICATIONS 8 CITATIONS

[SEE PROFILE](#)

Some of the authors of this publication are also working on these related projects:



Differentiating Papillary thyroid carcinoma from other thyroid lesion with similar histopathologic features by Negative expression of CD56 [View project](#)



Secondary and Tertiary Hyperparathyroidism can affect arterial stiffness in ESRD patients: A pilot study [View project](#)

All content following this page was uploaded by [Mohammad Aladaileh](#) on 27 October 2015.

The user has requested enhancement of the downloaded file. All in-text references [underlined in blue](#) are added to the original document and are linked to publications on ResearchGate, letting you access and read them immediately.

Case Report

Strangulated hernia with bowel perforation through a defect of the broad ligament

Mohammad S Al-Qudah, [Mohammad M Aladaileh](#), [Mohammad Z Rashdan](#),
[Mohamad E Abdullah](#), [Awni D Shahait](#)

Department of General Surgery, Faculty of Medicine, Jordan University Hospital, University of Jordan, Amman, Jordan

ABSTRACT

Intestinal obstruction is a very common cause for presentation to the Emergency Department while internal hernia is a rare cause of obstruction. Among internal hernias, defects of the broad ligament (BL) are extremely rare. Defects of the BL can be either congenital or secondary to surgery, pelvic inflammatory disease, and delivery trauma. Herein, we report a 43-year-old lady, who presented with signs and symptoms of perforated small bowel for which a diagnosis of acute peritonitis was made. At laparotomy, the cause of the perforation was found to be an internal hernia through a defect in the right BL. Surgical management was taken with a smooth postoperative course.

Key words: Bowel perforation, broad ligament, internal hernia, intestinal obstruction

Introduction

Intestinal obstruction is a common cause for presentation to the Emergency Department while internal hernia is a rare cause of such obstruction. Hernia through defects of the broad ligament (BL) is extremely rare.^[1] The diagnosis of this condition is usually not made preoperatively due to its rarity and nonspecific manifestation. This report describes a rare case of intestinal obstruction with bowel perforation from internal hernia through a defect in the right BL.

Case Report

A 43-year-old lady presented to the Surgical Department with vomiting, constipation, abdominal colic, and

distension for 3 days. She was known to have primary hypertension and old cerebrovascular accident. She had previous two cesarean sections. She was febrile. Abdomen was distended with central and right lower abdominal tenderness. There was localized peritonism in the right lower quadrant, with hyperactive bowel sounds. Leukocyte count was elevated to 18,000/mm³. Multiple air-fluid levels were seen on an erect abdominal radiograph. Computed tomography (CT) was done to rule out complicated intestinal obstruction, which showed dilated small bowel down to the distal ileum, focal wall thickening with closed loops (whirlpool sign) suggestive of closed loop obstruction with free fluid in upper abdomen and pelvis [Figure 1].

Patient was prepared with nasogastric tube and Foley's catheter insertion, hydration, and intravenous broad spectrum antibiotic (imipenem 500 mg 4 times daily). Diagnostic laparoscopy was decided because of closed loop obstruction and, which showed closed loop of the ileum herniating through a 4 cm defect in the right BL, the proximal bowel was markedly dilated, and the incarcerated portion was necrotic with perforation [Figure 2]. The operation was converted to an open laparotomy because of presence of perforation, which showed 20 cm long of nonviable bowel (80 cm from the ileocecal junction), which was resected and end to end one layer interrupted hand sewn anastomosis was performed. A 4 cm defect in the right BL was closed with 2.0 nonabsorbable suture.

Address for correspondence: Dr. Mohammad S. Al-Qudah,
Department of General Surgery, Faculty of Medicine, Jordan
University Hospital, University of Jordan, Amman, Jordan.
E-mail: msquda@yahoo.com

Access this article online

Quick Response Code:



Website:

www.archintsurg.org

DOI:

10.4103/2278-9596.167522

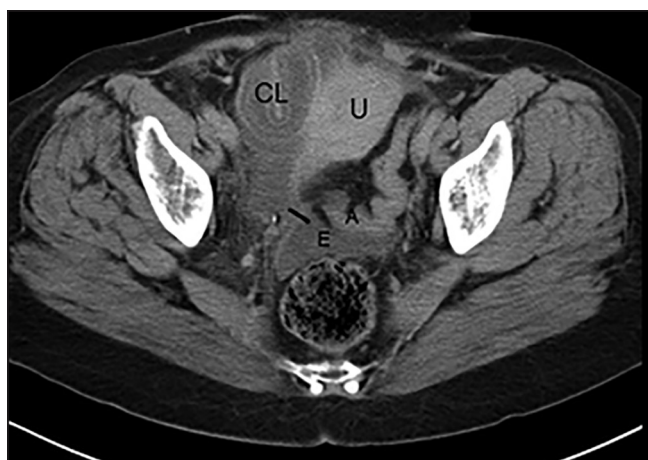

Figure 1: Computed tomography scan shows small bowel obstruction due to a broad ligament hernia (the black line at the defect), which is a closed-loop small bowel obstruction with a whirlpool sign closed loop (CL). The hernia located anterior to the uterus (U) pushing the uterus laterally to the left. Efferent and afferent ileal limbs (E and A, respectively.)

The patient had an uneventful postoperative recovery and was discharged home 5 days after surgery on oral antibiotic (cefuroxime 500 mg twice daily for 5 days). The histopathological report was consistent with gangrenous bowel.

Discussion

This is probably the first reported case of internal hernia through a defect of the BL with perforation of small bowel loop, as noted during surgical exploration. It is important to keep in mind the possibility of internal hernia because it may present with serious complication.

Internal hernias represent only 0.4-4.1% of all small bowel incarcerations, and of these, the hernias through a defect of the BL represent only 4% with only 28 reported cases.^[4] An internal hernia is defined as the protrusion of an intra-abdominal viscus through or into the retroperitoneal fossae or a mesenteric defect.^[2] The various types of internal hernias include paraduodenal hernias (53%), pericecal hernias (13%), hernias through the foramen of Winslow (8%), sigmoid related hernias (6%), and transmesenteric hernias (8%).^[2] Herniation of structures through a defect in the BL is even more uncommon and was first reported by Quain in 1861.

Hunt classified hernias of the BL into two types: The fenestra type that is caused by a complete fenestration through a defect in the BL as in the present case and the pouch type,^[3] which involves herniation into the pouch from an anterior or posterior opening.^[4] The etiology is unknown, nevertheless, congenital, and acquired causes

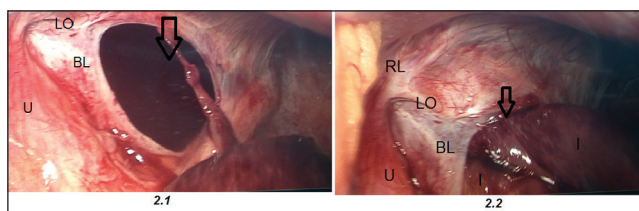


Figure 2: A laparoscopic picture is revealing a defect in the right broad ligament (BL) (black hollow arrow). Afferent and efferent ileal loops (I). The round ligament (RL), the ovarian ligament (LO), and the uterus (U)

had been reported. The acquired ones include previous surgeries, pregnancy and birth trauma, endometriosis, and pelvic inflammatory disease. There are 2 cases of unilateral congenital BL defect reported in English literature, first by Hiraiwa *et al.* in 2006^[4] and the 2nd case by Ngabou *et al.* in 2012.^[5] Review of the case reports revealed that the most common content of a hernia through a defect in the BL was the small bowel (25 out of 28 cases), especially the ileum. The sigmoid colon, cecum, appendix, and ovary have been reported to herniate through a BL defect resulting in complications such as bowel ischemia, ileovaginal fistula, and strangulation of the ovary.^[6] Our case is the first one, which presented with bowel perforation as a complication. The defect is usually unilateral and rarely bilateral. Other classification was mentioned by Cilley *et al.* in 1986 which was based on the anatomical location of the defect. Type 1: The most common (like in our case) the defect through the entire BL, type 2: Through the mesosalpinx or mesovarium, and type 3: Throughout the meso-ligamentum teres.^[3]

The preoperative diagnosis of an internal hernia through a defect in the BL is often difficult as the clinical picture of small bowel obstruction is nonspecific. However, there were 5 cases diagnosed by CT preoperatively.^[2] The pathognomonic radiological feature of small bowel obstruction due to a BL hernia, as in this case, is a closed loop small bowel obstruction with a hernia located lateral to the uterus as first described by Balthazar *et al.*^[2]

Laparoscopic surgery has gained an increasingly important role in the diagnosis and treatment of intestinal obstruction. The 1st case of laparoscopic repair of the hernia through a BL defect was reported by Guillem *et al.* in 2003, since that time, 13 out of 20 cases were carried out laparoscopically with an uneventful outcome, while the 8 cases before 2003 were managed by laparotomy.^[8,9] Diagnosis and effective surgical treatment of complicated internal hernia are challenging by laparoscopy, but it can be carried out through an open approach. In our patient, we converted to laparotomy because of safety and ease of accomplishment.

Conclusion

BL hernia is the rarest form of internal hernia that may lead to severe complications. It must be kept in mind as a possible cause of intestinal obstruction in females. CT scan may suggest the diagnosis. Diagnostic laparoscopy is ideal as it allows for definitive diagnosis and effective surgical treatment, but it can be carried out through an open approach. Early surgical treatment is mandatory in these cases to reduce morbidity and mortality from strangulation.

References

1. Cazzo E, Maciel OW, Neto OO, Miolo TL. Intestinal obstruction secondary to incarcerated broad ligament hernia: A case report. *OA Case Rep* 2013;2:34.
2. Tanaka M, Kaneko Y, Ietsugu K, Yoshida C. Internal herniation through a broad ligament defect after obturator hernia repair. *Surg Today* 1994;24:634-7.
3. Cilley R, Poterack K, Lemmer J, Dafoe D. Defects of the broad ligament of the uterus. *Am J Gastroenterol* 1986; 81:389-91.
4. Hiraiwa K, Morozumi K, Miyazaki H, Sotome K, Furukawa A, Nakamaru M. Strangulated hernia through a defect of the broad ligament and mobile cecum: A case report. *World J Gastroenterol* 2006;12:1479-80.
5. Ngabou UD, Hornez E, Chiron P, Fondin M, Pons F. Internal hernia through a defect in the broad ligament. *J Visc Surg* 2012;149:e161-2.
6. Quiroga S, Sarrias M, Sánchez JL, Rivero J. Small bowel obstruction secondary to internal hernia through a defect of the broad ligament: Preoperative multi-detector CT diagnosis. *Abdom Imaging* 2012;37:1089-91.
7. Balthazar EJ, Birnbaum BA, Megibow AJ, Gordon RB, Whelan CA, Hulnick DH. Closed-loop and strangulating intestinal obstruction: CT signs. *Radiology* 1992;185:769-75.
8. Guillem P, Cordonnier C, Bounoua F, Adams P, Duval G. Small bowel incarceration in a broad ligament defect. *Surg Endosc* 2003;17:161-2.
9. Lim SZ, Tan VKM, Teo MCC. Case Report of an Internal Hernia Through a Unilateral Congenital Defect of the Broad Ligament and Literature Review, *Proceedings of Singapore Healthcare*, 2012; 21:213-6.

How to cite this article: Al-Qudah MS, Aladaileh MM, Rashdan MZ, Abdullah ME, Shahait AD. Strangulated hernia with bowel perforation through a defect of the broad ligament. *Arch Int Surg* 2015;5:190-2.

Source of Support: Nil. **Conflicts of interest:** None declared.

